

Plummer thyroid adenoma: Back to the basic

Andra Cocolos^{1,2}, Nicoleta Dumitru^{1,2}, Eugenia Petrova¹, Mara Carsote^{1,2},
Ana Valea^{3,4}, Adina Ghemigian^{1,2}

¹"Carol Davila" University of Medicine and Pharmacy, Bucharest, Romania

²"C.I. Parhon" National Institute of Endocrinology, Bucharest, Romania

³"I. Hatieganu" University of Medicine and Pharmacy, Cluj-Napoca, Romania

⁴Clinical County Hospital, Cluj-Napoca, Romania

ABSTRACT

Plummer disease of the thyroid represents a traditional condition causing primary hyperthyroidism. Our aim is to introduce a short overview regarding the use of the term "Plummer adenoma" of the thyroid and to report a case with traditional diagnosis. In terms of method this is a case report and a historical data report using as references PubMed and online sites of general endocrine and historical information.

This is a 43-year old female who had 2 months ago a mild episode of vertigo, followed by intermittent sweating and weight loss (2 kilos within 2 months). Hyperthyroidism is confirmed based on suppressed TSH. Thyroid scintigram was performed using as thyroid tracer Tc99m Perthechnetate which revealed thyroid with normal anatomy with a "hot" autonomous nodule at the level of right thyroid lobe. Thyroid ultrasound showed a right lobe of 2.4 by 3.2 by 3.5 cm and a left lobe of 1.1 by 0.8 by 3.6 cm. Right lobe has a macronodule of 3.5 by 2.1 by 2.8 cm which entirely occupies the lobe; it has an inhomogeneous pattern, with microcalcifications and tracheal effect to the opposite site. The patient was offered daily thiamazole and a low dose of beta blockers; follow-up is necessary; then the indication of thyroidectomy will be done because of thyroid dimensions and nodule aspect in association with tracheal effect. Plummer toxic nodule of the thyroid represents a classical endocrine condition which requires thyroid scintigram to be adequately identified even the management is not distinctive from other forms of primary hyperthyroidism.

Keywords: Plummer adenoma, toxic goitre, hyperthyroidism

INTRODUCTION

Plummer disease of the thyroid represents a traditional condition causing primary hyperthyroidism (1-3). The specific condition underlying excessive thyroid function has, somehow, two meanings. Traditionally, the term is used (including for Romanian daily endocrine practice) for a dominant thyroid nodule with toxic activity regardless a single nodule or a dominant one from multinodular goitre (1-3). The typical image of this aspect is caught by specific pattern of radioiodine ¹³¹I uptake on thyroid scintigram based on the non-adenoma tissue inhibition caused by suppressed TSH (Thyroid Stimulating Hormone) as feedback to increased thyroid hormones production by the Plummer adenoma (4). However, there are some published data that intro-

duce the term of "Plummer disease" for toxic multinodular goitre meaning more than one nodule with increased activity opposite to single solitary active nodule (5).

Historically, the condition was first described by Henry Stanley Plummer in 1913 for a specific thyrotoxicosis condition with one or more toxic nodules, later the term was restricted to only one (6). Doctor Plummer is one of founders of Mayo Clinic from Minnesota (7).

Our aim is to introduce a short overview regarding the use of the term "Plummer adenoma" of the thyroid and to report a case with traditional diagnosis. In terms of method this is a case report and a historical data report using as references PubMed and online sites of general endocrine and historical information.

Corresponding author:

Assist. Prof. Mara Carsote, MD, PhD

E-mail: carsote_m@hotmail.com

Article History:

Received: 11 May 2018

Accepted: 25 May 2018

CASE PRESENTATION

This is a 43-year old female who is a former smoker and lives in endemic area for goitre. Her family history of diseases includes father with lung cancer and mother with chronic heart ischemic condition. Her personal medical history is irrelevant. Two months ago she had a mild episode of vertigo, followed by intermittent sweating and weight loss (2 kilos within 2 months). Neurological did not establish any particular diagnosis, cardiological evaluation identified sinus tachycardia and she was followed for an endocrine check-up. On admission, hyperthyroidism is confirmed based on suppressed TSH (of 0.0005 $\mu\text{UI/mL}$, normal levels between 0.5 and 4.5 $\mu\text{UI/mL}$), and increased FreeT4 (levothyroxine) twice as normal upper limits with negative antibodies against thyroid including TRAb (TSH Receptor Antibodies). Thyroid scintigramme was performed using as thyroid tracer Tc99 Perthechnetate which revealed thyroid with normal anatomy with a “hot” autonomous nodule at the level of right thyroid lobe (Fig. 1). In addition, thyroid ultrasound showed a right lobe of 2.4 by 3.2 by 3.5 cm (centimetre) and a left lobe of 1.1 by 0.8 by 3.6 cm. Right lobe has a macronodule of 3.5 by 2.1 by 2.8 cm which entirely occupies the right lobe; it has an inhomogeneous pattern, with microcalcifications and tracheal effect to the opposite site (Fig. 2). The patient was offered daily thiamazole and a low dose of beta blockers; follow-up is necessary; then the indication of thyroidectomy will be done because of thyroid dimensions and nodule aspect in association with tracheal effect.

DISCUSSION

Plummer toxic nodule is a benign one, associating T3 and T4 hyper-production which suppresses TSH and displays a specific “hot” nodule on thyroid scintigram performed with either radioiodine or technetium (3). The approach is surgical or ablative with radioiodine after initial anti-thyroid drugs administration in order to normalize the thyroid function (8-10). Cases first diagnosed at very old age after a long term of subclinical hypothyroidism have been reported (11).

Plummer toxic adenoma is rarer found that classical causes of thyrotoxicosis Basedow-Graves disease and multinodular goitre (12). The clinical approach of the condition including therapeutically options and thyroid surgery are not specific for this sub-type of hyperthyroidism (13). The case we mentioned was not confirmed as Plummer toxic nodule until thyroid scintigram was done, as known from literature.

As particular aspect, we mention the presence of microcalcifications at thyroid ultrasound which are frequently considered a sign of increased risk for papillary thyroid cancer while Plummer adenoma is 99% of cases benign (14-16).

CONCLUSION

Plummer toxic nodule of the thyroid represents a classical endocrine condition which requires thyroid scintigramme to be adequately identified even the management is not distinctive from other forms of primary hyperthyroidism.

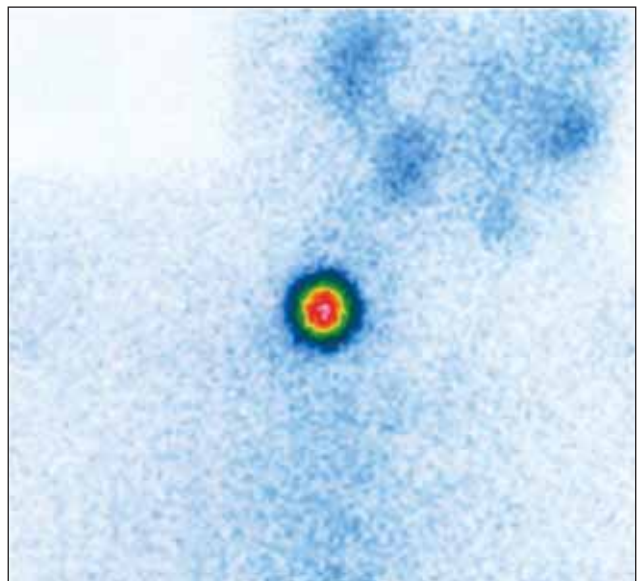
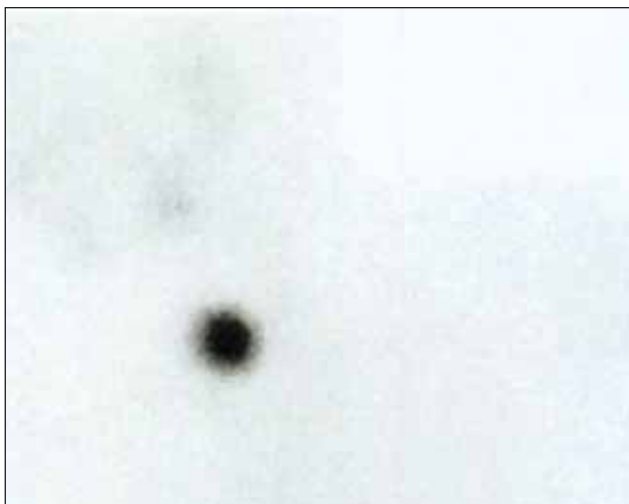
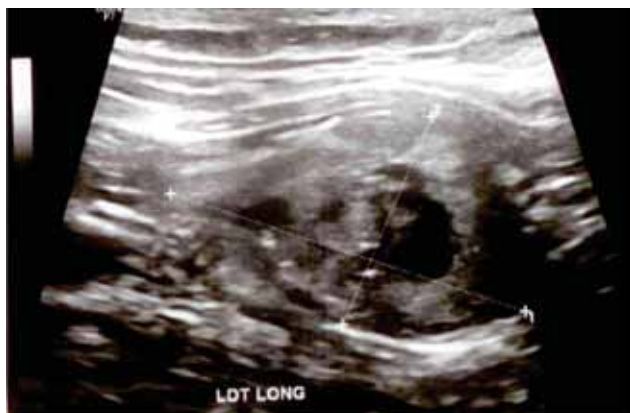
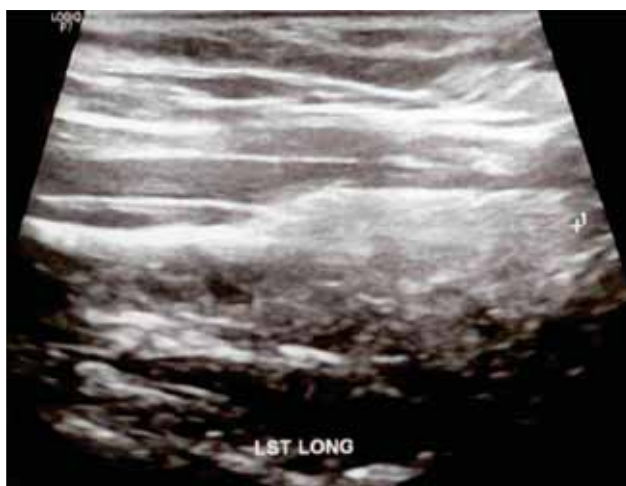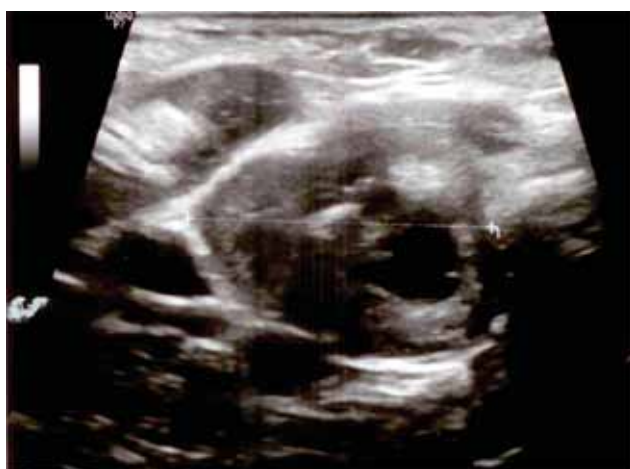FIGURE 1. This is a 43-year old female with thyrotoxicosis Thyroid scintigramme was performed using as thyroid tracer Tc99 Perthechnetate which revealed thyroid with normal anatomy with a “hot” autonomous nodule at the level of right thyroid lobe. This is the typical aspect for Plummer toxic nodule



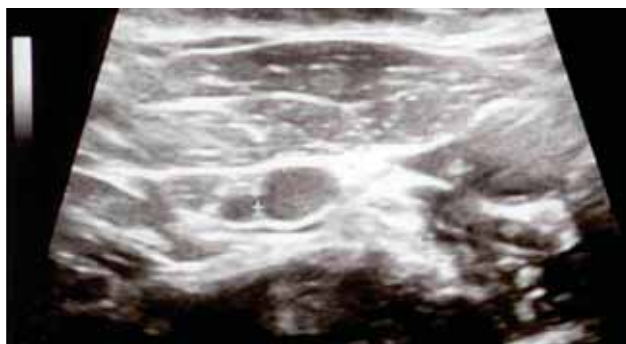
A (longitudinal aspect)



B (longitudinal aspect)



C



D

FIGURE 2. This is a 43-year old female with Plummer toxic adenoma. Thyroid ultrasound showed a right lobe of 2.4 by 3.2 by 3.5 cm (centimetre) (A) and a left lobe of 1.1 by 0.8 by 3.6 cm (B) Right lobe has a macro-nodule of 3.5 by 2.1 by 2.8 cm which entirely occupies the right lobe (C); it has an inhomogeneous pattern, with microcalcifications and tracheal effect to the opposite site. A small right cervical lymph node of 0.8 by 0.8 cm is also detected (D)

REFERENCES

1. Wellman H.N., Anger R.T. Jr. Properties, production and clinical uses of radioisotopes of iodine. *CRC Crit Rev Clin Radiol Nucl Med.* 1975 Feb; 6(1):81-111.
2. <http://www.endocrinesurgeon.co.uk/index.php/what-is-plummers-disease>
3. Wiener J.D. Autonomously functioning thyroid nodules (Plummer disease). *J Pediatr.* 1977 Oct; 91(4):682-3.
4. Feliciano D.V. Image of the month. Toxic adenoma or solitary autonomous nodule (variant of Plummer disease). *Arch Surg.* 2001 Feb; 136(2):239-40.
5. <https://www.britannica.com/science/Plummer-disease>
6. https://en.wikipedia.org/wiki/Henry_Stamley_Plummer
7. <http://history.mayoclinic.org/>
8. Ross D.S., Burch H.B., Cooper D.S., Greenlee M.C., Laurberg P., Maia A.L., Rivkees S.A., Samuels M., Sosa J.A., Stan M.N., Walter M.A. 2016 American Thyroid Association Guidelines for Diagnosis and Management of Hyperthyroidism and Other Causes of Thyrotoxicosis. *Thyroid.* 2016 Oct; 26(10):1343-1421.
9. Smith D.L. Thyroid disease: Medical or surgical management? *J Am Osteopath Assoc.* 1974 Apr; 73(8):624-9.
10. Bahn Chair R.S., Burch H.B., Cooper D.S., Garber J.R., Greenlee M.C., Klein I., Laurberg P., McDougall I.R., Montori V.M., Rivkees S.A., Ross D.S., Sosa J.A., Stan M.N.; American Thyroid Association; American Association of Clinical Endocrinologists. Hyperthyroidism and other causes of thyrotoxicosis: Management guidelines of the American Thyroid Association and American Association of Clinical Endocrinologists. *Thyroid.* 2011 Jun; 21(6):593-646.
11. Hasegawa T., Araki A., Tamura Y., Sugawara T., Iwata A., Kamimiyama F., Chiba Y., Horiuchi T., Mori S., Ito H. A case of Plummer disease that appeared in older old age after 10-year course of subclinical hyperthyroidism. *Nihon Ronen Igakkai Zasshi.* 2007 Mar; 44(2):251-5.
12. De Leo S., Lee S.Y., Braverman L.E. Hyperthyroidism. *Lancet.* 2016 Aug 27; 388(10047):906-918.
13. Villar del Moral J.M., Soria Aledo V., Colina Alonso A., Flores Pastor B., Gutiérrez Rodríguez M.T., Ortega Serrano J., Parra Hidalgo P., Ros López S. Clinical Pathway for Thyroidectomy. *Cir Esp.* 2015 May; 93(5):283-99.

14. Whittle C., García M., Horvath E., Slater J., Carrasco C. Thyroid Microcalcifications in the Absence of Identifiable Nodules and Their Association With Thyroid Cancer. *J Ultrasound Med.* 2018 May 21. doi: 10.1002/jum.14667. [Epub ahead of print]
15. Ning C.P., Ji Q.L., Fang S.B., Wang H.Q., Zhong Y.M., Niu H.T. Distribution patterns of microcalcifications in suspected thyroid carcinoma: A classification method helpful for diagnosis. *Eur Radiol.* 2018 Jun; 28(6):2612-2619.
16. Kang J., Chung W.Y., Kang S.W., Kwon H.J., Yoo J., Kim E.K., Chang J.H., Song T.K., Lee S., Kwak J.Y. Ex vivo estimation of photoacoustic imaging for detecting thyroid microcalcifications. *PLoS One.* 2014 Nov 21; 9(11):e113358. doi: 10.1371/journal.pone.0113358. eCollection 2014.

Conflict of interest: none declared
Financial support: none declared