

DENOSUMAB MANDIBULAR ADVERSE EVENT IN NIVOLUMAB TREATED PATIENT

Xenia Elena Bacinschi^{1,2}, Anca Zgura², Philippe Glorieux³, Jacques Olette⁴, Françoise Derouane⁵,
Rodica Anghel^{1,2}

¹ Department of Oncology-Radiotherapy, „Prof. Dr. Alexandru Trestioreanu“ Institute of Oncology, Bucharest, Romania

² „Carol Davila“ University of Medicine and Pharmacy, Bucharest, Romania

³ Hematology-Oncology Department, Cliniques Sud Luxembourg, Arlon, Belgium

⁴ Radiology Department, Cliniques Sud Luxembourg, Arlon, Belgium

⁵ Catholic University of Louvain, Belgium

ABSTRACT

Recently we assisted in the important progress development of immune checkpoint inhibitors in oncology especially in advanced disease. Among other several localizations (malignant melanoma, lung, bladder, head, and neck), advanced renal cell carcinoma benefit from Nivolumab an anti-PD1 (anti-programmed cell death protein 1) approval.

Immune-related side effects are reported in almost 90% of cases and are mainly cutaneous and digestive. Grade 3 or more immune-related side effects occur in much lower incidence and are more present in a patient receiving anti-CTLA4 antibodies or a combination of immune checkpoint inhibitors. Between the cited are very rare, thus being isolated reported are musculoskeletal manifestations.

Herein we report a case of a 73-year-old female patient who, after 9 months of treatment with Nivolumab, as a 3rd line treatment for clear cell renal metastatic carcinoma, developed a mandibular osteitis. For more than two years, the patient has been undergoing Denosumab for secondary bone lesions and as a first line systemic treatment, she has received an anti-VEGF-TKI (vascular endothelial growth factor-tyrosine kinase inhibitor) for 16 months. At both product discontinuation and under oral corticosteroids, the clinical signs have regressed but the radiologic follow-up of 6 months later showed an evolution to an osteonecrosis. This patient was referred to a stomatological intervention.

We propose this case report as a reflection of the consequence of adding Nivolumab to a long-term Denosumab treatment, after an oral anti-angiogenic exposure.

Keywords: osteitis, Nivolumab, Denosumab, osteonecrosis of the jaw, immunotherapy

BACKGROUND

The backbone of a therapeutic strategy in metastatic clear cell renal carcinoma is represented by anti-angiogenic and mammalian rapamycin inhibitors.

In this localization, due to the immunogenic character of the tumour, interleukin 2 (IL-2) and interferon alpha (IFN- α) have been previously approved, despite their modest effectiveness (1).

Nivolumab is the first immune checkpoint PD1 (anti-programmed cell death protein 1) inhibitor, approved in pretreated metastatic renal carcinoma

patients based on survival benefit over Everolimus in CheckMate 025 phase 3 study (median overall survival 25.0 months vs 19.6 months, HR: 0.73; 95% CI [0.60-0.89]) (1,2).

One of the mechanisms of immune checkpoint inhibitors (ICIs) is to target the pathways that inhibit immune cell activation and to lead an increase of anti-tumour response (3,4).

Compared to CTLA-4 (cytotoxic T-lymphocyte-associated protein 4) anti-PD1/PD-L1 appears to be better tolerated. Grade 3-4 immune-mediated toxicities are reported between 7% and 12%, frequently being gastrointestinal, dermatological, en-

dochrine, pulmonary and hepatic (5,6). Musculo-skeletal side effects are very rarely described in the literature and are rather myositis and arthritis, the latter affecting mainly the large joints (7,8).

Denosumab is a monoclonal antibody that blocks ligand binding to the receptor activator of a nuclear factor Kappa-B (RANK) and is approved for the prevention of skeletal-related events (SRE) in patients with bone metastases (9). The common side effects related to Denosumab are hypocalcemia, osteonecrosis of the jaw (ONJ), atypical femoral fracture and infections (9). The incidence of ONJ under posology for bone metastasis ranges from 1% to 2% (10). Furthermore, a mechanism of bone loss induced by activated lymphocytes T has been pointed out by Kong YY and colleagues as early as 1999 (11).

There are very few cases in the literature reporting the concomitant administration of a checkpoint inhibitor and an anti-RANK or osseous event occurred under Nivolumab or immunotherapy in general. Consequently, we reported this case of mandibular osteitis developed in a patient concomitantly receiving both types of products.

CASE REPORT

A 73 years old woman with neither personal or family cancer-related antecedents, nor infectious personal history, was diagnosed in October 2014 with metastatic renal cell carcinoma. She was addressed for back pain and the radiological evaluation showed a lytic lesion of the right sacroiliac area and furthermore, a technetium-99m (Tc-99m) uptake was recorded in L1-L2 and L4-L5 regions of the lumbar spinal column.

The diagnostic workup revealed the presence of a left renal tumour of 5 centimeters in diameter and pulmonary nodular lesions. The biopsy of the right sacroiliac osseous mass confirmed the histology of a clear renal cell carcinoma (CK7- (cytokeratin 7), CK20- (cytokeratin 20), EMA+ (epithelial membrane antigen), CD10 (of CALLA, acute lymphoblastic leukaemia antigen) +).

As the stage, according to the AJCC seventh edition was IV and the prognosis, according to International Metastatic Renal Cell Carcinoma Database Consortium (IMDC) score was intermediate, an upfront treatment of oral Pazopanib, a VEGF-targeted molecule, of 800mg daily, and Denosumab 120mg subcutaneously, every four weeks, has been initiated. At baseline, both dental scan and liver blood tests were normal. Despite a stable disease, revealed by two months later radiological fol-

low-up, a grade III hepatic impairment attributable to Pazopanib (according to CTCAE v4.03) (12) was registered (AST x4, ALT x10, GGT x30, total bilirubin x2) and the systemic treatment was changed in favour of Axitinib.

As progression was recorded in July 2016, meaning after 16 months of VEGF- TKI (vascular endothelial growth factor-tyrosine kinase inhibitor), an anti PD1 inhibitor, Nivolumab 3 mg/kg every 2 weeks, has been started. At the 9th month's reassessment, in February 2017, the response was partial according to iRECIST criteria (13).

In March 2017, few days following the twentieth infusion of Nivolumab, the patient developed a pain in a jaw, irradiating up to the temporomandibular joints, around grade 4 on a visual scale of pain (EVA), with no fever. On examination, chin oedema and erythema were noticed, and no intra-oral lesion or satellite adenopathy have been observed. Biologically, the CRP (C reactive protein) was elevated (74 mg/l) with no leukocytosis. A beta-lactam antibiotic and NSAID (Non-steroidal anti-inflammatory) drug, Ibuprofen 1200mg/day, were prescribed for 14 days, with no amelioration.

Right at the end of the 21st Nivolumab infusion, the pain became more and more intense (EVA 6/10), developing into a neuropathic one, and yet no clinical or biological (CRP of 89.10mg/l) amelioration has been registered. Supposing a mandibular osseous complication, it was decided to discontinue Denosumab administration and the NSAID has been changed in favour of Naproxen 1,500 mg per day, for a total of 7 days. The 22nd cycle of anti PD1 (EVA 8/10) lead to an aggravation of the pain, thus the antalgic treatment was upheld to step II oral mild opioid by Tramadol 150 mg/day, and the Nivolumab was withheld in May 2017.

The paraclinical examinations, the bone of scintigraphy Tc99m performed in May 2017 showed an intense and diffuse uptake in the mandible (figure 1).

The bone CT showed a periosteal apposition in the horizontal branch of the mandible, several lacunar elements on an overall densification of the bone trabeculae, without pathological infiltration of the soft tissues (figure 2).

The MRI (magnetic resonance imaging) examination displayed a hyposignal in T1 sequence and a moderate hyper signal in T2 in the body of the mandibular body, up to its rising branches, enhancing moderately after injection of gadolinium, with an infiltration in hypersignal T2 of the neighbouring fat tissues, signs compatible with an osteitis (Figure 3).

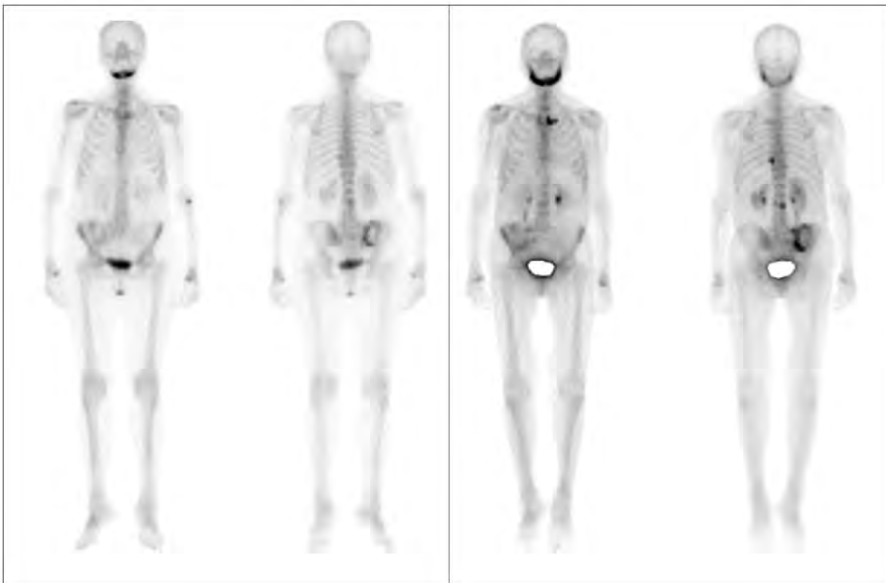


FIGURE 1. Bone scintigraphy Tc99m. Evolution of the uptake of the mandible from May 2017 (on the left) to October 2017 (on the right)

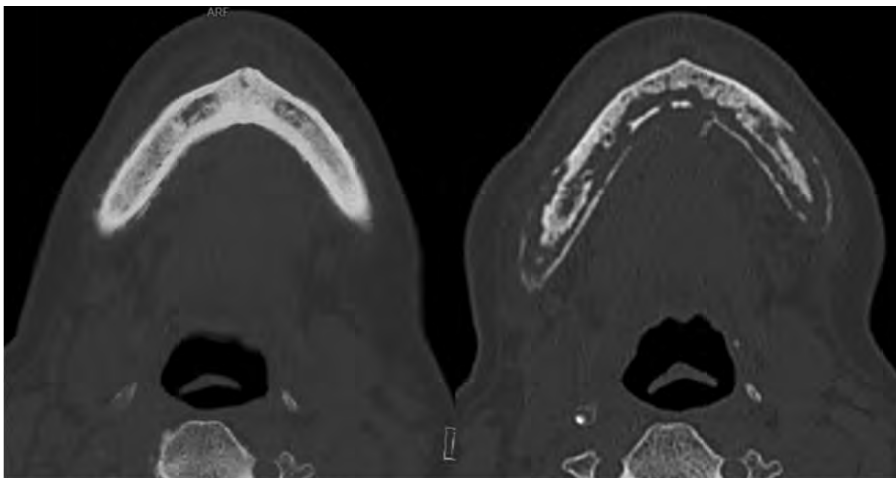


FIGURE 2. Bone CT of the mandible. On the left, June 2017 and on the right, December 2017.

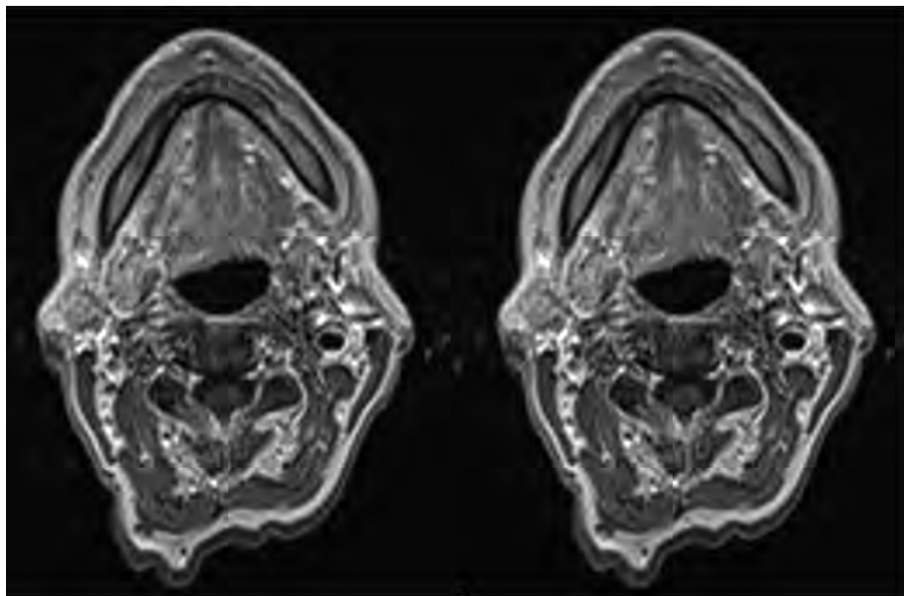


FIGURE 3. Evolution of the RMN of the mandible from June 2017 (on the left) to January 2018 (on the right)

The standard radiological examination did not show any lytic or condensate lesion.

As the pain has been increasing, likewise the inflammatory syndrome (CRP of 101,70mg/l), the diagnosis of mandibular osteitis has been retained and a treatment with Prednisone was started (15 mg/day meaning 0.5 mg/kg). After only 7 days of corticoid treatment, clinical and biological improvement has been reached: the background pain scores decreased to 2-3/10 on EVA and CRP declined to 62.20 mg/l. The dose of Prednisone was tapered during a period of 1 month, while the clinical evolution continued to be favourable with nearly complete regression of the chin oedema and erythema and pain regression, nevertheless with a residual hyperesthesia in the territory of mandibular right branch projection. The stomatological evaluation found no need for any specific intervention. The CT scan reassessment in October 2017, after 6 months of a therapeutic brake, showed a progressive disease in the liver and in the lung and therefore the systemic treatment has been changed in favour of Everolimus. At this time, a bone scintigraphy Tc99m was done and showed a bilateral extension with an intense hyperactivity on both mandibles. On December 2017 there was still existing slight pain in the mandibular area and the targeted radiological follow up showed an interesting CT severe heterogeneity, the horizontal branch of the mandible with extension towards the base of the rising branches sparing the mandibular condyles, an infiltration of nearby soft tissues, consistent with extensive bone necrosis within the chronic osteitis. The RMI performed at this time showed an osteonecrosis of the jaw in the area of the chronic osteitis described previously.

The patient has been referred to stomatological intervention and is still continuing the oral therapy of Everolimus.

DISCUSSIONS

ONJ under Denosumab

Denosumab is a bone-modifying monoclonal antibody that specifically targets the RANK ligand thereby preventing the osteoclast formation. In oncology, it is indicated for bone loss prevention in patients under therapeutic hormone deprivation and skeletal-related events (SREs) reduction in bone metastasis from solid tumor (9) the posology being 60 mg every 6 months or 120 mg every 4 weeks respectively, by subcutaneous injection.

One of the relatively frequent adverse events of its long-term use is osteonecrosis of the jaw (ONJ),

the risk becoming higher over time and by cumulative dose, beyond 12 months of the monthly administration (14-16).

The diagnosis of ONJ is mainly clinical and radiological, the classical symptoms being odontalgia, tooth mobility, erythema, ulceration, paresthesia, anaesthesia of the associated branch of the trigeminal nerve (10); intraoral or extraoral fistulae might be observed when the necrotic zone becomes infected.

In order to consider the medication-related aetiology (MRONJ), the clinical signs should have developed under a current or previous antiresorptive or antiangiogenic agent without any history of radiation therapy or obvious metastatic disease of the jaws.

There are non-exposed variants of ONJ described in the literature (17,18) where the pain is the foreground and there is no communication created between the mandibular bone and the surrounding tissues as ulceration or fistulation (10).

In our patient, jaw pain was the main symptom and evolved to a neuropathic one at the mandibular joint level. Concomitantly, a chin oedema and erythema have been developed without any intraoral lesion, exposed bone or fistulae, and no associated fever. The histopathological features of the ONJ are not specific and could not cut off between the two conditions; hence no bone biopsy was prescribed in this case (10,19).

Radiological and scintigraphic aspects of ONJ

The standard radiological examination usually shows the non-specific modifications such as thickening of the lamina dura, increased trabecular density or periodontal ligament space widening. In bone tomodensitometry imaging, diffuse osteosclerosis, areas of osteolysis, cortical erosion or increased periosteal bone formation and sequestration can be described (10).

In our case, a panoramic radiograph did not show any sign of modification in the mandibular area. The first bone tomodensitometry highlighted periosteal apposition of the horizontal branch of the mandible, several lacunar elements and an overall densification of the bone trabeculae without the pathological infiltration of the soft tissues, considered as mandibular osteitis. The bone scan performed six months later showed a severe heterogeneity of the horizontal branch of the mandible with extension towards the base of the rising branches sparing the mandibular condyles and an infiltration of the soft tissues. These images were

compatible with an extensive bone necrosis, on a background chronic osteitis.

MRI seems to be superior for bone marrow evaluation and tissue changes. The early stages of ONJ, when the tissues are infiltrated, the MRI usually showed a decrease of bone marrow signal intensity on T1 weighted images with an intensification of the signal on T2-weighted sequences and short T1 inversion recovery (STIR) is described. In case of osteolysis, an irregular gadolinium enhancement of bone marrow and of the soft tissues is observed. In advanced stages, the intensity T2-weighted and short T1 inversion recovery can be variable (10).

In our patient, the mandibular MRI performed at 3 months after the symptom onset showed a hyposegmental signal in T1 sequence and a moderate hyper signal in T2 in the mandible, up to its rising branches, enhancing moderately after injection of gadolinium. An associated infiltrative hyper signal in T2 sequences, it was revealed in the neighbouring fat tissues; these findings were interpreted as an osteitis (figure 2 and 3).

Bone scintigraphy with Tc99m MDP (methylene diphosphonate) or HDP (hydroxy diphosphonate) is highly sensitive right from early phases of ONJ when it shows an increased uptake in the concerned areas (10).

The initial bone scintigraphy run in our patient showed an intense and diffuse uptake in the mandible and several months later showed an extension of the hyper fixation on both mandibles compatible with ONJ (Figure 1 and 3).

Rheumatologic and musculoskeletal adverse events under anti PD1/PDL1

Rheumatologic and musculoskeletal adverse events have been observed rarely in patients undergoing checkpoint inhibitor treatment (4,5). Nevertheless, according to a recent systematic review of the literature, the percentage of reported arthralgia ranged 1-43% and myalgia ranged 2-20% (6).

The incidence of articular adverse events seems higher in Pembrolizumab (anti-PDL1) or Nivolumab (anti-PD1) treated patients than in those exposed to Ipilimumab (anti-CTLA 4) (4,6).

The large and small joints are similarly at risk and the interval between treatment setup and the occurrence of musculoskeletal symptoms range from 2 to 13 months, tending to persist several months even after the treatment discontinuance (6).

The temporomandibular articular pain described by our patient had developed 9 months from the

start of immunotherapy and it had the particularity to increase in intensity right during or at the end of Nivolumab infusion, even though Denosumab was withheld. Despite anti PD-1 discontinuance, the symptoms continued to persist at the same intensity until the corticoid introduction.

Osteitis and ONJ under checkpoint inhibitors

Among the pharmaceutical products named to possibly lead to a medication-related osteonecrosis of the jaw (MRONJ), Ipilimumab is included thus pointing out the checkpoint inhibitor class (20).

In general, the moderate or severe adverse events under immunotherapy require treatment interruption and immunosuppression by corticosteroids. For patients with grade 2 (moderate) immune-mediated toxicities, treatment with the checkpoint inhibitor should be withheld and should not be resumed until symptoms or toxicity is grade 1 or less. Corticosteroids (prednisone 0.5 mg/kg/day or equivalent) should be started if symptoms do not resolve within a week (6). In patients with grade 2 of MRONJ, the base of the treatment strategies is an antibiotic therapy (10,17).

In our case, the treatment with a beta-lactam antibiotic performed for 14 days in association with an NSAID lead to no clinical or biological amelioration. As the pain has been increasing, despite the discontinuance of Nivolumab and Denosumab and in the hypothesis of a mandibular osteitis, the treatment with Prednisone was started (15 mg/day meaning 0.5 mg/kg). The clinical and biological improvements have been observed after only 7 days of treatment with a decrease of pain and the CRP decline. At the corticoid withdrawal, no symptom relapse was observed.

To our knowledge, there is only one case in the literature regarding the concomitant administration of an immune-checkpoint inhibitor and a RANK ligand inhibitor with no osteoarticular adverse event reported and only one case of mandibular toxicity under Ipilimumab (21).

CONCLUSIONS

Even if no histopathological evidence was obtained in our case, the radiological findings on CT scan and on IRM and the clinical evolution support the initial diagnosis of osteitis of the mandibular bone body with evolution to MRONJ.

The condition could have been favoured by long-term Denosumab exposure, the concomitant use of an oral antiangiogenic and revealed by the

anti PD1 administration through the mechanism of bone loss and periosteal inflammation by systemic activation of T cells.

Taking into account the lack of amelioration observed under antibiotics and NSAID, the intensification of pain right after the Nivolumab administration and the real clinical, biological and

radiological benefit under corticoids, the hypothesis of an initial immune-related osteitis are strengthened.

Afterward, the ONJ has been progressed leading to radiological et scintigraphic findings in favour of.

REFERENCES

- Rodriguez-Vida A, Hutson TE, Bellmunt J, Strijbos MH. New treatment options for metastatic renal cell carcinoma. *ESMO Open* 2017;2:e000185.
- Motzer RJ, Escudier B, McDermott DF, George S, Hammers HJ, Srinivas S, et al. Nivolumab versus Everolimus in Advanced Renal-Cell Carcinoma. *N Engl J Med*. 2015; 373:1803-1813.
- Rotte A, Jin JY, Lemaire V. Mechanistic overview of immune checkpoints to support the rational design of their combinations in cancer immunotherapy. *Ann Oncol*. 2017;0:1-13.
- Davies M, Duffield EA. Safety of checkpoint inhibitors for cancer treatment: strategies for patient monitoring and management of immune-mediated adverse events. *ImmunoTargets and Therapy* 2017(6) 51-71.
- Wang X, Bao Z, Zhang X, Li F, Lai T, Cao C et al. Effectiveness and safety of PD-1/PD-L1 inhibitors in the treatment of solid tumours: a systematic review and meta-analysis. *Oncotarget*. 2017;8 (35) 59901-59914.
- Naidoo J, Page DB, Li BT, Connell LC, Schindler K, Lacouture ME, et al. Toxicities of the anti-PD-1 and anti-PD-L1 immune checkpoint antibodies. *Ann Oncol*. 2015 Dec;26(12):2375-91.
- Capelli LC, Gutierrez AK, Bingham CO, Shah AA. Rheumatic and musculoskeletal immune-related adverse events due to immune checkpoint inhibitors: a systematic review of the literature. *Arthritis Care Res (Hoboken)*. 2017;69(11):1751-1763.
- Widmann G, Nguyen VA, Plaickner J, Jaschke W. Adverse effects of immunotherapy: Clinical aspects, radiological and nuclear medicine results. *Radiology*. 2017 Jul 21.
- Costa AG, Bilezikian JP. How long to treat with Denosumab. *Curr Osteoporos Rep* (2015) 13:415-420.
- Khan AA, Morrison A, Hanley DA, Felsenberg D, McCauley LK, O’Ryan F, et al. Diagnosis and management of osteonecrosis of the jaw: a systematic review and international consensus. *J Bone Miner Res*. 2015;30(1):3-23.
- Kong YY, Feige U, Sarosi I, Bolon B, Tafuri A, Morony S, et al. Activated T cells regulate bone loss and joint destruction in adjuvant arthritis through osteoprotegerin ligand. *Nature*. 1999; 402:304-9.
- Common Terminology Criteria for Adverse Event (CTCAE), Version 4.0 published: May 28, 2009 (v4.03: June 14, 2010). NIH publication; no 90-5410.
- Seymour L, Bogaerts J, Perrone A, Ford R, Schwartz LH, Mandrekars S, et al. iRECIST: guidelines for response criteria for use in trials testing immunotherapeutics. *Lancet Oncol*. 2017 Mar;18(3):e143-e152.
- Qaisi M, Hargett J, Loeb M, Brown J, Caloss R. Denosumab Related Osteonecrosis of the Jaw with Spontaneous Necrosis of the Soft Palate: Report of a Life-Threatening Case. *Case Rep Dent*. 2016;2016:5070187.
- Bamias A, Kastritis E, Bamia C, Moulopoulos LA, Melakopoulos I, Bozas G, et al. Osteonecrosis of the jaw in cancer after treatment with bisphosphonates: incidence and risk factors. *J Clin Oncol*. 2005;23(34):8580-8587.
- Diz P, Lopez-Cedrun JL, Arenaz J, Scully C. Denosumab-related osteonecrosis of the jaw. *J Am Dent Assoc*. 2012;143(9):981-984.
- Schiodt M, Reibel J, Otuari O, Kofod T. Comparison of nonexposed and exposed bisphosphonate-induced osteonecrosis of the jaw: a retrospective analysis from the Copenhagen cohort and a proposal for an updated classification system. *Oral Surg Oral Med Oral Pathol Oral Radiol*. 2014;117:204-13.
- Ruggiero SL, Dodson TB, Fantasia J, Goodday R, Aghaloo T, Mehrotra B, et al. American Association of Oral and Maxillofacial Surgeons position paper on medication-related osteonecrosis of the jaw – 2014 update. *J Oral Maxillofac Surg*. 2014; 72(10):1938-1956.
- Fassio A, Bertoldo F, Idolazzi L, Viapiana O, Rossini M, Gatti D. Drug-induced osteonecrosis of the jaw: The state of the art. *Reumatismo* 2017;69 (1):9-15.
- Owosho AA, Scordo M, Yom SK, Randazzo J, Chapman PB, Huryn JM, et al. Osteonecrosis of the jaw a new complication related to Ipilimumab. *Oral Oncol*. 2015;51(12):e100-1.
- Smyth MJ, Yagita H, McArthur GA. Combination anti-CTL4 and anti-RANKL in metastatic melanoma. *J Clin Oncol*. 2016;34:104-106.