

# COCHLEAR EXPLANTATION – SURGICAL AND AUDIOLOGICAL ASPECTS

Dan Cristian Gheorghe<sup>1,2</sup>, Veronica Epure<sup>1,2</sup>

<sup>1</sup> ENT Department, “M.S. Curie” Clinical Emergency Hospital, Bucharest, Romania

<sup>2</sup> “Carol Davila” University of Medicine and Pharmacy, Bucharest, Romania

## ABSTRACT

Cochlear explantation is rare in surgical practice; it can be due to medical conditions or device failure. According to literature datas, there are some particularities to be expected in revision surgery. The authors describe a case of successful explantation followed by reimplantation, with excellent results, pointing out on the surgical difficulties encountered.

**Keywords:** cochlear implantation, fibrosis, osteoneogenesis

## INTRODUCTION

Overall the cochlear explantation rate is very low (1.5-2.2%) (1,2). Explantation is due to either to medical causes (wound infection and flap necrosis, hematoma due to head trauma, cholesteatoma, allergy to silicone, electrode or receiver migration) (1,3,4) or device failure (hard or soft failure).

A hard failure of the implant means lack of communication between the internal and external hardware, resulting in no sound perception. A soft failure means both external and internal hardware are properly functioning, the electrode is properly placed and overall the implant is not functioning. Symptoms of soft failure may include decreased performance and speech perception with the implant, subjective discomfort or pain while stimulating the implant (tinnitus, vertigo, facial nerve stimulation, pain).

If reimplantation follows explantation, it can be done simultaneously or staged (5).

Medical and audiological outcomes of explantation – reimplantation are generally excellent (6,7).

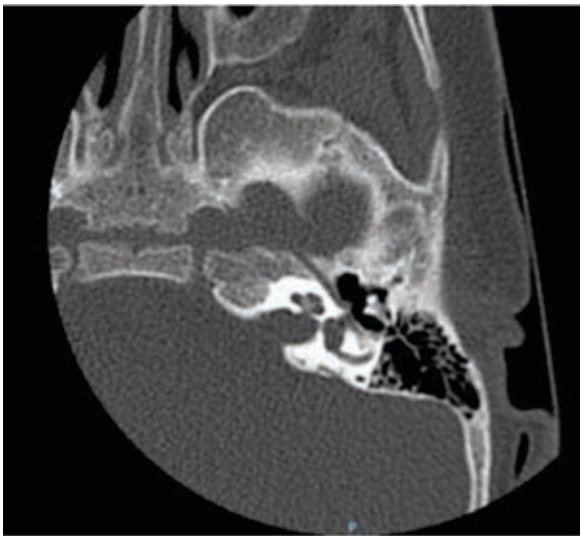
Different authors mention surgical difficulties linked to explantation and reimplantation: a moderate amount of fibrosis in the cochlea lumen mak-

ing reinsertion of the electrode challenging, osteoneogenesis in the mastoid cavity (6).

The authors report a case of cochlear explantation in a child, followed by reimplantation in the same surgical sitting. We received the informed consent of the patient’s parents both for surgical treatment and follow-up, and for including some of the anonymised data of the patient in the case report.

## CASE PRESENTATION

Our patient D.I. first presented to our department at the age of 2, with profound bilateral sensorineural hypoacusia and delay of language development, no other ENT or general pathology (besides allergy to amoxicillin-clavulanate). After complete audiological and imagistic investigations (CT – figure 1 and MRI) we decided and performed cochlear implantation in the left ear (Oticon device, november 2019). The postoperative evolution was fine, with activation of the implant at 5 weeks postoperatively; the child followed the fitting sessions and speech therapy recovery recommended by our protocole, with good understanding and speech development results.

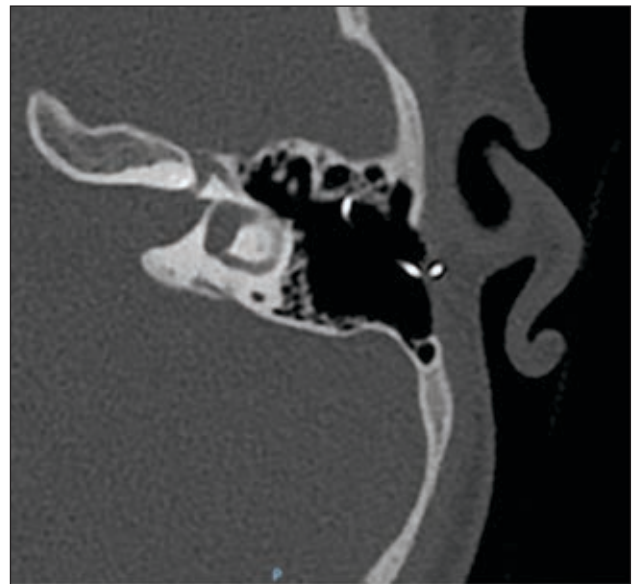


**FIGURE 1.** CT image before the first cochlear implantation (2019)

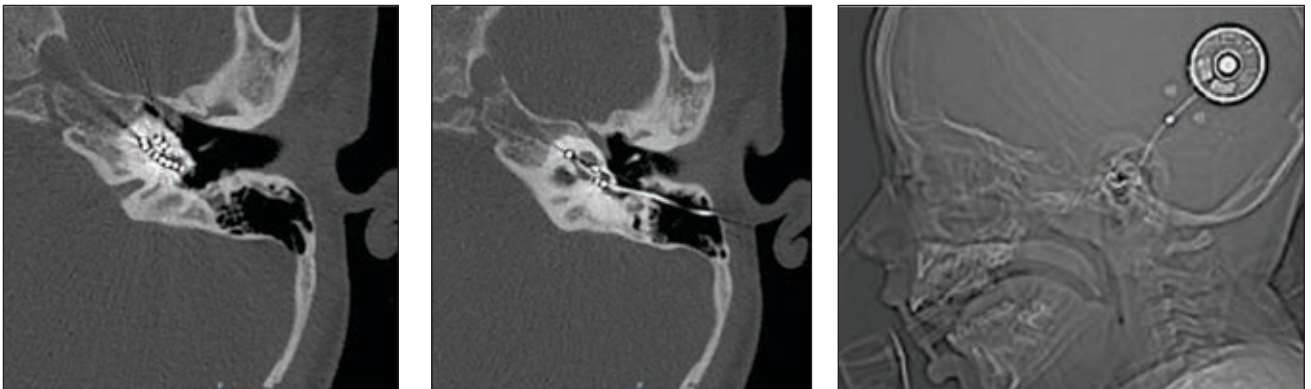
In March 2021, at the age of 4, the child presents to our department, accusing decreased performance and speech perception with the implant for 2 months, in the absence of head trauma. The measured impedances of the implant's electrodes were fine, the CT performed in this case (March 2021) showed no migration of the electrode or internal processor (figure 2), there were no local changes of the left retroauricular area, the ENT exam was completely normal.

Suspecting a device malfunction we decided and performed cochlear explantation followed immediately by reimplantation with the same type of device (March 2021). The CT images performed preoperatively (figure 3) drew attention to the osteoneogenesis process in the mastoid cavity. In fact, immediately after incision of skin and subcutaneous tissues, we noticed intense fibrosis, and osteogenesis around the external part of the electrode, making dissection difficult (figure 4). After thorough dissection of fibrous tissue surrounding

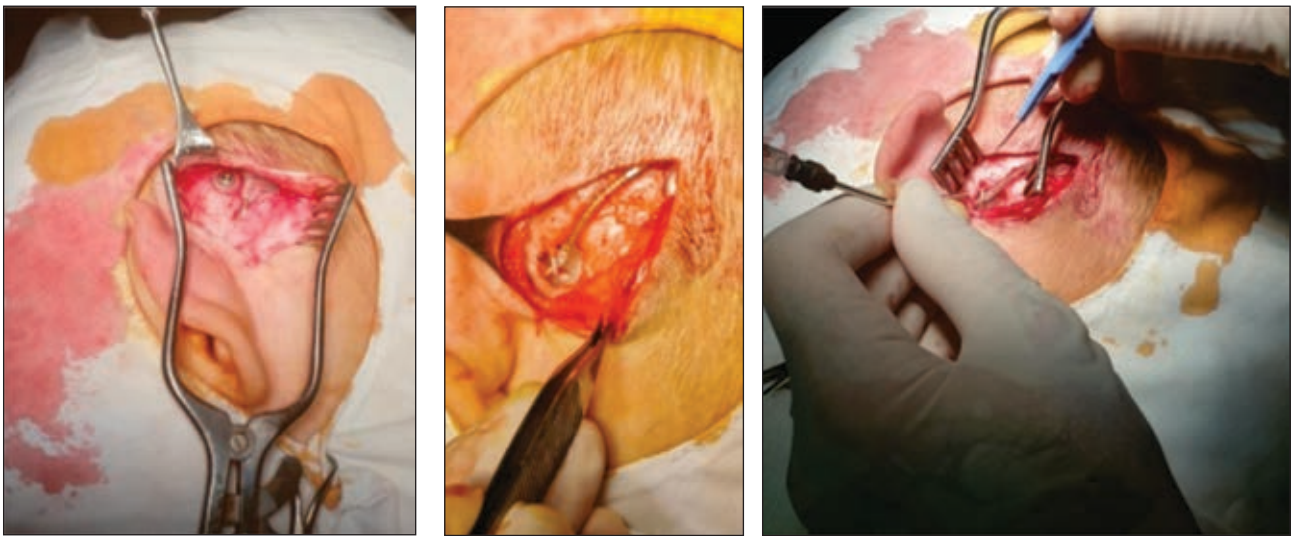
the electrode, the mastoid cavity was visible, significantly modified because of osteoneogenesis; new bone fixating the external part of the electrode at the edge of the mastoid cavity was carefully drilled, in order not to damage the implant; there was mild fibrosis at the level of the posterior tympanotomy and cochleostomy, needing fine dissection. The extraction of the electrode from the cochlea went smoothly. In order to minimise the time with open cochlea, we first extracted the old processor, leaving the electrode in place, then fixed the new processor with 2 screws in place, then removed the old electrode and inserted the new one (figure 5). Fine resistance was encountered at first attempt to insert the electrode through the cochleostomy (probably due to cochlear ossification), but after minimal drilling of the edge of the cochleostomy, the new electrode went in smoothly, with full insertion.



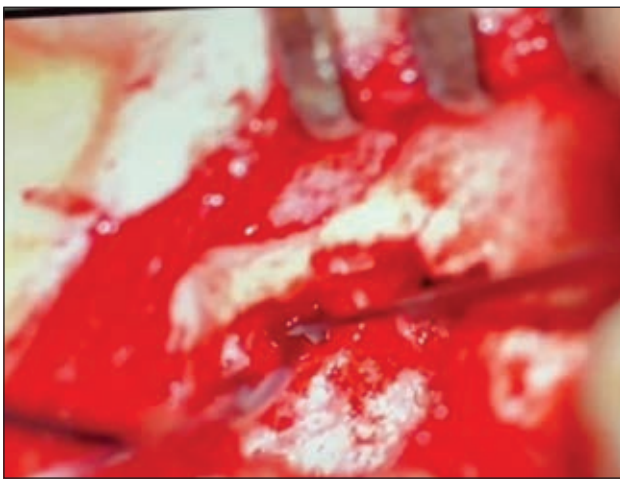**FIGURE 3.** Osteoneogenesis is visible on CT images before explantation (new bone surrounding the electrode at the level of mastoid edge)



**FIGURE 2.** CT images (March 2021) showing intracochlear positioning of the electrode and no migration of the processor



**FIGURE 4.** Intraoperative images during explantation showing intense fibrosis and osteoneogenesis in and around mastoid cavity



**FIGURE 5.** Intraoperative aspect – the old electrode remained in the cochlea while preparing the new device

Intraoperative audiological measurements (NRTs, impedances) were good, accounting for

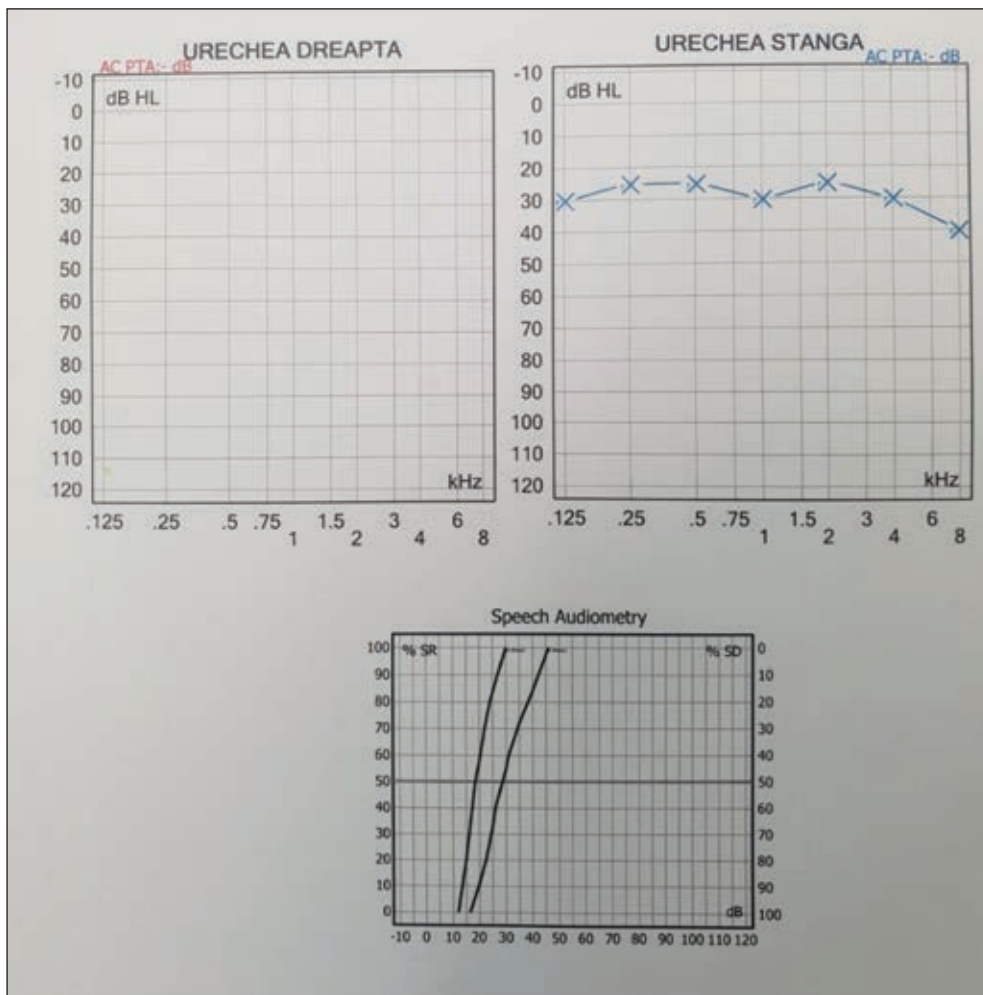
correct insertion of the electrode. Postoperative evolution of the patient was uneventful, under intravenous antibiotic (Meropenem); he returned 4 weeks later to our audiology department for implant activation, with excellent results (figure 6); afterwards only 2 fitting sessions were needed in order to obtain normal hearing with the implant.

## DISCUSSION

Cochlear explantation is very rare, thus there is few literature data on the subject. From our department's experience, with 12 years of cochlear implantation in children and more than 350 implants performed, there were only 2 cases of explantation. First there was the case of a 15 years old girl requesting definitive explantation because of personal convictions; in this case complete explantation was performed, leaving no electrode into the cochlea, as reimplantation was excluded. Secondly came the presented case, where explantation was immediately followed by reimplantation.

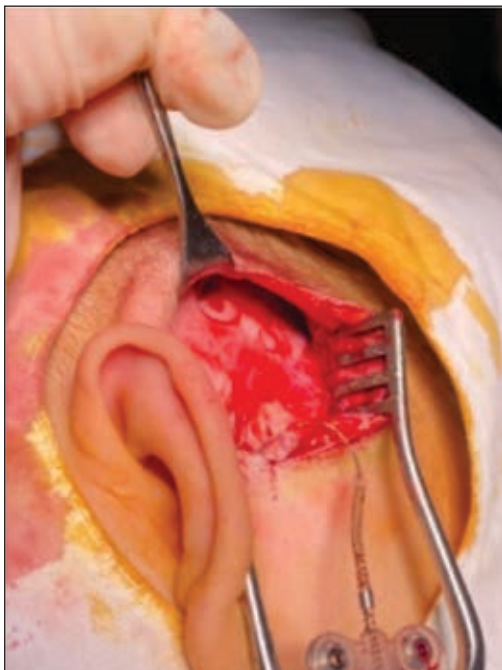Revision surgery on mastoid cavities is always





**FIGURE 6.** Free-field audiometry during first fitting session showing near-to-normal hearing with the implant

a challenge to the surgeon, because of modification of surgical landmarks, fibrosis and osteoneogenesis, especially in children (8); in our case, the



**FIGURE 7.** Previous implant bed and electrode groove

need to extract the implant without damaging it, in order to be technically analysed – added difficulty to the explantation. Intense fibrosis and remodeling of local tissues were common findings in this case, needing thorough dissection, drilling of the new bone at the mastoid cavity edge and at the cochleostomy level.

Ossification of the cochlea is always possible late after cochlear implantation, making reinsertion of another electrode difficult (5). In case of staged reimplantation, some authors recommend that the first electrode is retained in situ until final surgery, in order to prevent infection or ossification of the cochlear duct; in our case the lumen of the cochlea was permeable, with mild ossification of the cochlea opening.

In order to minimise the time during which the cochlea remained open – increasing the risk of infection - we first extracted the old processor, leaving the electrode in place until reinsertion of the new one.

Although there is no need for implant bed drilling with Oticon devices, which are fixed with 2 screws, after extracting the old device, we noticed

a newly formed "implant bed" and electrode groove (figure 7), carved into the skull bone by the implant itself – another proof of bone plasticity in children.

In our case, after analysing the extracted device, a conclusion of device failure was made. The audiological outcome after reimplantation was thus good, correspondant with literature data (9).

## CONCLUSION

Each and every case of cochlear implantation is different and surgically unique, but cochlear explantation can be challenging, especially in children, because of bone and soft tissue plasticity.

## REFERENCES

1. Jumah AN, Sakran YA. Causes and frequency of cochlear explantation. *Int J Surg Sci.* 2020;4(2):571-575.
2. Roby BB, Ferrello M, Huang TC, Rimell FL, Levine SC. Symptom timeline preceding cochlear implant failure: an institutional experience. *Otolaryngol Head Neck Surg.* 2012 May;146(5):782-7.
3. Roehm PC, Gantz BJ. Cochlear implant explantation as a sequela of severe chronic otitis media: case report and review of the literature. *Otol Neurotol.* 2006 Apr;27(3):332-6.
4. Kunda LD, Stidham KR, Inserra MM, Roland PS, Franklin D, Roberson JB Jr. Silicone allergy: A new cause for cochlear implant extrusion and its management. *Otol Neurotol.* 2006 Dec; 27(8):1078-82.
5. Ray J, Proops D, Donaldson I, Fielden C, Cooper H. Explantation and reimplantation of cochlear implants. *Cochlear Implants Int.* 2004 Dec;5(4):160-7.
6. Côté M, Ferron P, Bergeron F, Bussi eres R. Cochlear reimplantation: causes of failure, outcomes, and audiologic performance. *Laryngoscope.* 2007 Jul;117(7):1225-35.
7. Yeung J, Griffin A, Newton S, Kenna M, Licameli GR. Revision cochlear implant surgery in children: Surgical and audiological outcomes. *Laryngoscope.* 2018 Nov;128(11):2619-2624.
8. Lee J, Eddington DK, Nadol JB. The histopathology of revision cochlear implantation. *Audiol Neurootol.* 2011;16(5):336-46.
9. Zeitler DM, Budenz CL, Roland JT Jr. Revision cochlear implantation. *Curr Opin Otolaryngol Head Neck Surg.* 2009 Oct;17(5):334-8.