Ref: Ro Med J. 2022;69(Suppl3)
DOI: 10.37897/RMJ.2022.S3.7

Appendicular mucocele mimicking a right adnexal mass – a case report and literature review

Nicolae Bacalbasa[1,2], Irina Balescu[3], Claudia Stoica[4,5], Cristina Martac[6], Valentin Varlas[1,7], Andrei Voichitoiu[1,8], Lucian Pop[1,8], Sorin Petrea[9], Mihaela Vilcu[9,10], Iulian Brezean[9,10], Corina Grigoriu[1,11]

[1]Department of Obstetrics and Gynecology, "Carol Davila" University of Medicine and Pharmacy, Bucharest, Romania
[2]Department of Visceral Surgery, Center of Excellence in Translational Medicine, Fundeni Clinical Institute, Bucharest, Romania
[3]Department of Visceral Surgery, Ponderas Academic Hospital, Bucharest, Romania
[4]Department of Anatomy, "Carol Davila" University of Medicine and Pharmacy, Bucharest, Romania
[5]Department of Surgery, Ilfov County Emergency Hospital, Bucharest, Romania
[6]Department of Anesthesiology, Fundeni Clinical Institute, Bucharest, Romania
[7]Department of Obstetrics and Gynecology, Filantropia Clinical Hospital, Bucharest, Romania
[8]Department of Obstetrics and Gynecology, "Alessandrescu-Rusescu" National Institute of Mother and Child Care, Bucharest, Romania
[9]Department of Surgery, "Dr. I. Cantacuzino" Clinical Hospital, Bucharest, Romania
[10]Department of Surgery, "Carol Davila" University of Medicine and Pharmacy, Bucharest, Romania
[11]Department of Obstetrics and Gynecology, Emergency University Hospital, Bucharest, Romania

ABSTRACT

The correct diagnostic of a cystic lesion at the level of the right iliac fossa in women can be hard to be established in certain cases, different pathological lesions having similar imagistic aspects and being associated with similar biological modifications. In such cases the final diagnostic is established intraoperatively and the type of surgery can be significantly modified. The aim of the current paper is to report a 63 year old woman with preoperative diagnostic of right ovarian mass who was submitted to surgery in order to have a total hysterectomy and bilateral adnexectomy; however intraoperatively the cystic lesion developed at the level of the right iliac fossa proved to be an appendicular tumor and was successfully resected by performing a radical right hemicolectomy.

Keywords: ovarian cyst, appendicular mucocele, CA 125, right iliac fossa cystic mass

INTRODUCTION

The presence of abdominal pain at the level of the right iliac fossa might represent a significant diagnostic dilemma especially in women. Therefore, in such cases the most important differential diagnostics which should be discussed are represented by appendicitis, appendicular tumor, ovarian cyst or tumor, extrauterine pregnancy and pyosalpinx [1]. However, the final diagnostic might be difficult to be established preoperatively, the final diagnostic being an intraoperative surprise which enables the surgeon to completely modify the therapeutic plan as well as the surgical procedure. The aim of the current paper is to report the case of a 63 year old patient investigated for diffiuse abdominal pain at the level of the right iliac fossa and in whom the preoperative diagnostic was of an adnexal cystic mass.

CASE REPORT

The 63 year old previously healthy patient was investigated for abdominal pain at the level of the right iliac fossa and she was submitted to an abdominal and respectively transvaginal ultrasound which demonstrated the presence of a 14/13 cm cystic mass at the level of right adnexal area. The patient was further submitted to a pelvic magnetic resonance imaging which confirmed the presence of a 14/10/15 cm mass originating probably at the level of the

Corresponding author:
Nicolae Bacalbasa
E-mail: nicolae_bacalbasa@yahoo.ro

Article History:
Received: 18 April 2022
Accepted: 28 April 2022

FIGURE 1. Initial intraoperative aspect – large cystic mass originating from the appendix

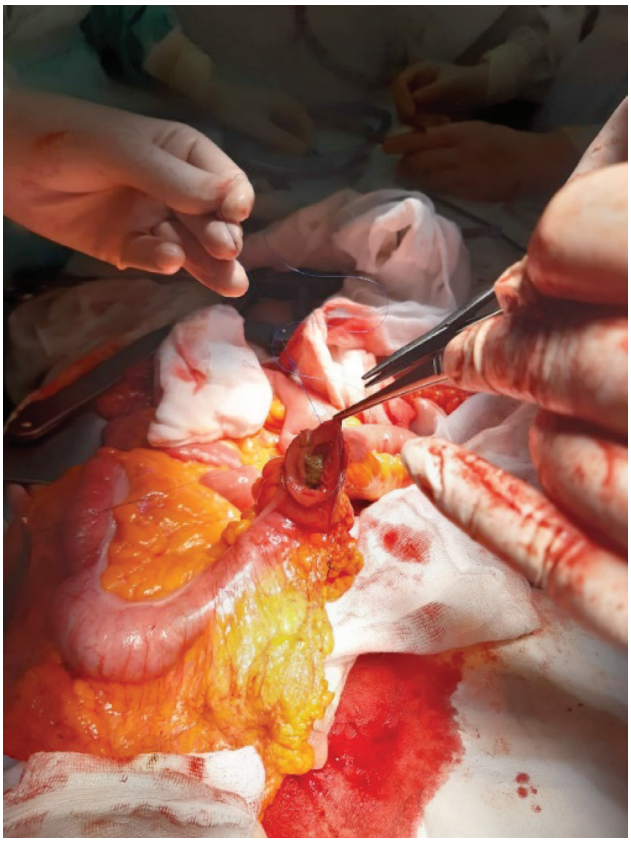

FIGURE 2. The aspect after right radical hemicolectomy – performing ileo-colic anastomosis

FIGURE 3. The specimen of right colectomy en bloc with the tumoral lesion at the level of the appendix

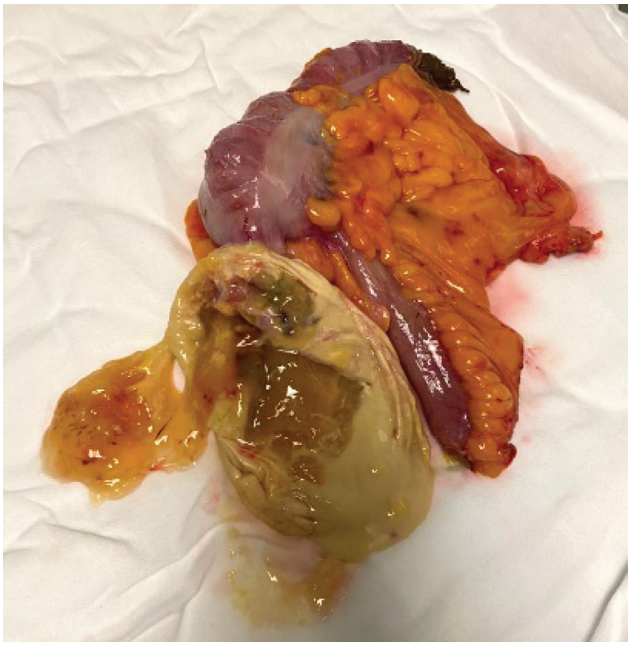

FIGURE 4. The specimen after being sectioned – exteriorization of a large amount of mucin

right adnexa. The bioumoral studies revealed a slightly increased level of CA125 measuring 75 U/ml. in this respect, after discussing with the patient the fact that the most probable diagnostic was of a right ovarian cystic tumor decision was taken to perform a total hysterectomy with bilateral adnexectomy. However, the intraoperative surprise was represented by the fact that the right iliac fossa cystic mass originated in fact from the appendix while the right adnexa was perfectly normal. Therefore, the surgical procedure was converted into a right radical colectomy with ileo-colic anastomosis (Figures 1-4). The histopathological studies confirmed the presence of a low potential malignant appendicular mucocele while the postoperative outcome was a simple one, the patient being discharged in the third postoperative day.

DISCUSSIONS

The differential diagnostic of adnexal masses includes multiple entities such as ovarian cysts, tubal or tubo-ovarian abscesses, extrauterine pregnancy; meanwhile, excepting gynecological disorders, the most commonly diagnostic which should be excluded originating from the gastrointestinal sphere is represented by appendicular tumors [2]. When it comes to appendiceal mucocele, it represents a gastrointestinal malignancy which is more commonly encountered in postmenopausal women and which might be associated with common symptoms such as right iliac fossa pain, and, in rare cases, with atypical signs such as vaginal bleeding [3-5]. Interestingly, less than 30% of appendiceal mucinous tumors are correctly identified during the preoperative investigations, most of them being misdiagnosed as adnexal masses at transvaginal or transabdominal ultrasound or even at computed tomography or pelvic magnetic resonance imaging [6].

Another interesting subject which should be discussed is the one of the value of CA125 in differentiated appendiceal mucocele by ovarian cysts; unfortunately, increased values are encountered in both pathologies and therefore, a modification of the serum values of CA 125 should not be considered as pathognomonic for an ovarian pathology; however, in cases in which the right fossa mass originates from the digestive tract (including the appendix) a slightly increased serum level of carcinoembryonic antigen (CEA) might orientate the diagnostic [7,8].

When it comes to the most appropriate therapeutic strategy in such cases, different strategies have been proposed; therefore, if during a laparoscopic exploration for right fossa mass a appendiceal mucocele is found, while certain authors consider that conversion to open surgery is mandatory, other authors consider that the procedure can be finalized in a minimally invasive manner if effraction and intraperitoneal spillage can be prevented [9,10]. However, irrespective to the approach type, peritoneal cytology should be retrieved and if malignant cells are encountered, hyperthermic intraperitoneal chemotherapy should be proposed; meanwhile in such cases certain authors consider bilateral oophorectomy mandatory due to the possible tumoral contamination of the ovaries [11,12].

When it comes to the risk of recurrence after resection of appendiceal neoplasms and to the main follow up methods, it seems that a combination between imagistic studies and serum levels of tumor markers such as CEA and CA 125 might be useful in order to assess remission or reaparition of the disease [13].

CONCLUSIONS

Establishing the right diagnostic in a postmenopausal woman presenting a tumoral mass at the level of the right inguinal area remains a veritable challenge especially due to the fact that similar symptoms, bioumoral modifications and imagistic findings might be encountered. Therefore, in a significant number of cases the final diagnostic remains to be established intraoperatively. However, once an appendicular mucocele is found, the intraoperative approach and the final therapeutic decision is taken accordingly to the extent of the disease.

Conflict of interest: none declared
Financial support: none declared

REFERENCES

1. Givens V, Gregg Mitchell C, Harraway-Smith AR, Maness DL. Diagnosis and Management of Adnexal Masses. 2009; 15;80(8):815-20.
2. Papoutsis D, Protopappas A, Belitsos P, Sotiropoulou M, Antonakou A, Loutradis D et al. Mucocele of the vermiform appendix misdiagnosed as an adnexal mass on transvaginal sonography. *J Clin Ultrasound.* 2012;40(8):522–525.
3. Akman L, Hursitoglu BS, Hortu I, Sezer T, Oztekin K, Avsargil BD. Large-mucinous neoplasm of the appendix mimicking adnexal mass in a postmenopausal woman. *Int J Surg Case Rep.* 2014;5:1265–1267.
4. Cristian DA, Grama FA, Becheanu G, Pop A, Popa I, Surlin V, Stanilescu S et al. Low-grade appendiceal mucinous neoplasm mimicking an adnexal mass. *Rom J Morphol Embryol.* 2015;56:837–842.
5. Toffaha A, El Ansari W, Aleter A. What you see might not be what you get: Discrepancies between intraoperative findings and preoperative diagnosis of ovarian tumors. Appendicular mucocele presenting as an adnexal mass - Case report and review of literature. *International Journal of Surgery Case Reports.* 2020;75:543–549.
6. Ruiz-Tovar J, Teruel DG, Castineiras VM, Dehesa AS, Quindós PL, Molina EM. Mucocele of the appendix. *World J Surg.* 2007;31:542–548.
7. Voorzanger-Rousselot N, Garnero P. Biochemical markers in oncology. Part I: molecular basis. Part II: clinical uses. *Cancer Treat Rev.* 2007;33:230–283.
8. Mandai M, Konishi I, Tsuruta Y, Suginami N, Kusakari T, Iwasaki T, Fujii S. Krukenberg tumor from an occult appendiceal adenocarcinoid: a case report and review of the literature. *Eur J Obstet Gynecol Reprod Biol.* 2001;97:90-95.
9. Foula MS, Alardhi AM, Othman SA, Khalid Mirza Gari M. Laparoscopic management of appendicular mucinous cystadenoma, case report. *Int J Surg Case Rep.* 2019;54:87–9.
10. Dhage-Ivatury S, Sugarbaker P. Update on the surgical approach to mucocele of the appendix. *J Am Coll Surg.* 2006;202(4):680–684.
11. Agrusa A, Romano G, Galia M, Cucinella G, Source V, Di Buono G et al. Appendiceal mucinous neoplasms: an uncertain nosological entity. *Report of a case. G Chir.* 2016;37:86–89.
12. Gillion JF, Franco D, Chapuis O, Serpeau D, Convard JP, Jullès MC et al. Appendiceal mucoceles, pseudomyxoma peritonei and appendiceal mucinous neoplasms: update on the contribution of imaging to choice of surgical approach. *J Chir* (Paris). 2009;146(2):150-166.
13. Glasgow SC, Gaertner W, Stewart D, Davids J, Alavi K, Paquette IM et al. The American Society of Colon and Rectal Surgeons, Clinical Practice Guidelines for the Management of Appendiceal Neoplasms. *Dis Colon Rectum*. 2019;62:1425–1438.