

# Non-syndromic oropharyngeal hamartoma: A case report

Kanwar Vikrant Singh, Gurpreet Singh, Surabhi Gupta, Paromita Patra

Department of Otorhinolaryngology, MGM & LSK Hospital Kishanganj Bihar, India

## ABSTRACT

This case report details the presentation, investigation, management, and histopathological examination of a rare occurrence – non-syndromic oropharyngeal hamartomas in a 2-year-old child. The child presented with a substantial orofacial mass on the dorsum of the tongue, causing significant functional impairments. Notably, the mass measured 8×4 cm and protruded outside the oral cavity. Additional findings included a nodular mass at the tongue tip, a lobulated mass on the right buccal mucosa (3×4 cm), cleft palate, microphthalmos of the right eye, and an accessory pinna on the right cheek.

Diagnostic investigations, including ultrasound, revealed irregular soft tissue lesions with hypoechoic areas and vascular channels, indicative of hemangioma. Blood parameters were within normal limits. Due to the size and symptomatic nature of the mass, surgical intervention was planned and executed under general anesthesia with nasal intubation. The procedure involved complete dissection and excision of the masses from the tongue and buccal mucosa. The surgical site was meticulously closed in layers using 4-0 vicryl.

Postoperatively, the child resumed oral feeds on the third day, and the recovery period was uneventful. Histopathological examination of the excised specimen depicted a hamartomatous lesion of the tongue characterized by stratified squamous epithelial lining, admixture of blood vessels, adipose tissue, fibrocollagenous tissue, cartilaginous tissue, nerve bundles, adnexal structures, and minor salivary glands.

The report concludes by highlighting the rarity of lingual hamartomas, emphasizing the exceptional size and vascularity of the presented case. It stresses the necessity of considering hamartomas in the differential diagnosis of tongue lesions in pediatric patients. The definitive management approach discussed is complete surgical excision, with the importance of confirming the diagnosis through histopathological examination of the excised specimen. This case contributes with valuable insights into the clinical presentation and management of non-syndromic oropharyngeal hamartomas in pediatric patients.

**Keywords:** non-syndromic, oropharyngeal, hamartoma, tissue lesions, tongue, excision, pediatric

## INTRODUCTION

Hamartomas, characterized by the benign proliferation of mature tissue specific to the organ of origin, present an intriguing subset of medical conditions, particularly when manifesting within the oral region. This case report delves into the exceptional and infrequently observed occurrence of large and multiple oral hamartomas in a 2-year-old child, a presentation remarkably devoid of any associated syndromes [Yi-Chun Carol Liu MD (2020)]. The scarcity of such non-syndromic instances accentuates the uniqueness of this case and prompts a closer examination of the complexities surrounding oral hamartomas.

In the realm of oral pathology, hamartomas, though recognized, are seldom encountered, making this case a notable addition to the limited corpus of reported instances. While these benign tumors can emerge independently, they sometimes accompany syndromes such as oral-facial-digital syndrome, which underscores the clinical significance of this particular non-syndromic presentation [Vashishth A, Mathur NN (2014)]. With only a sparse 63 cases reported in the English literature not associated with identifiable syndromes [Kreiger PA, Ernst LM, Elden LM (2007)], this report contributes to the evolving understanding of the spectrum of oral hamartomas and emphasizes the need for heightened awareness in

Corresponding author:  
Paromita Patra  
E-mail: info@gdpublishers.com

Article History:  
Received: 8 January 2024  
Accepted: 30 March 2024

both clinical and academic settings. The diagnostic journey becomes all the more intriguing' as this report unfolds the intricacies of a congenital orofacial mass in a pediatric patient, emphasizing the multifaceted challenges it posed to essential functions like feeding, breathing, and speech. The absence of perinatal complications in the child's history adds a layer of complexity, urging a comprehensive exploration of potential etiological factors contributing to the development of such a distinctive oral pathology. In light of the rarity of non-syndromic oral hamartomas, this case report serves as a valuable contribution to the medical literature, aiming to enrich our understanding of these unique manifestations, their diagnostic considerations, and the tailored management strategies required for optimal patient outcomes. The subsequent sections delve into the clinical, investigative, and therapeutic facets of this case, painting a comprehensive picture of the challenges and triumphs encountered in addressing this extraordinary presentation of oral hamartomas in a pediatric context.

## HISTORY

The historical narrative of this case unfolds against the backdrop of a 2-year-old child grappling with a congenital orofacial mass, which significantly impacted essential functions such as feeding, breathing, and speech. Born at term without perinatal complications, the child's antenatal history was notably unremarkable, adding an element of surprise to the clinical presentation. The onset of symptoms associated with the orofacial mass, occurring early in the child's life, underscores the congenital nature of the condition. The challenges posed by the mass highlight its impact on crucial developmental milestones, creating a compelling context for thorough investigation and intervention. The absence of perinatal complications adds a layer of complexity to the diagnostic puzzle, raising questions about the etiological factors contributing to the development of such a unique oral pathology. Exploring potential genetic, environmental, or developmental influences becomes paramount in understanding the origin and evolution of the congenital orofacial mass in this pediatric case. In the broader context of pediatric oral pathology, the case's historical dimension prompts reflections on the potential prenatal and neonatal factors that might have set the stage for the manifestation of this distinctive condition. As the clinical narrative progresses, the historical aspects become integral in shaping a comprehensive understanding of the case, guiding subsequent examinations, investigations, and ultimately, the formulation of a targeted and effective management strategy.

## EXAMINATION

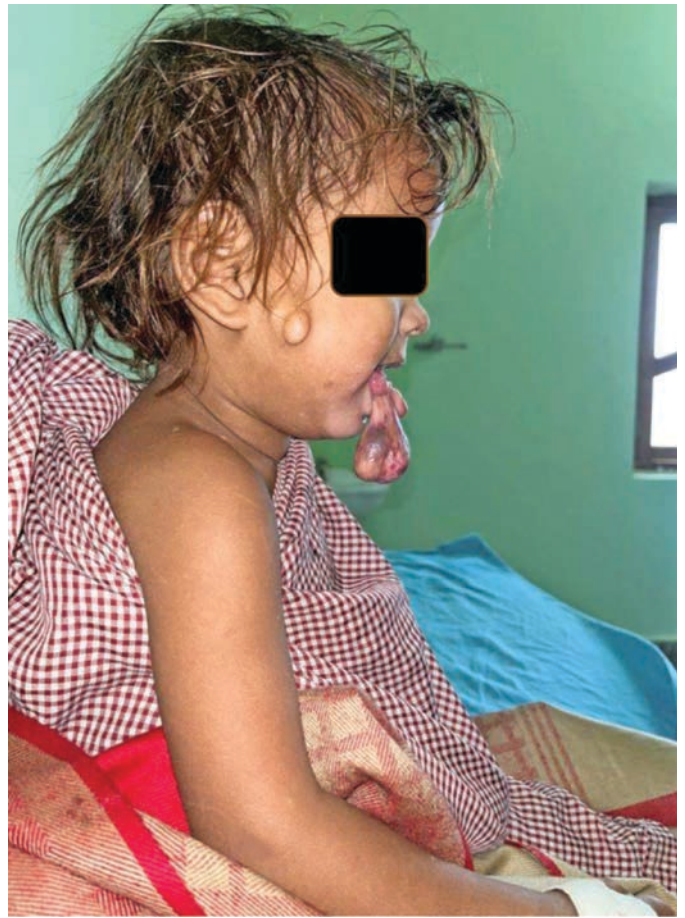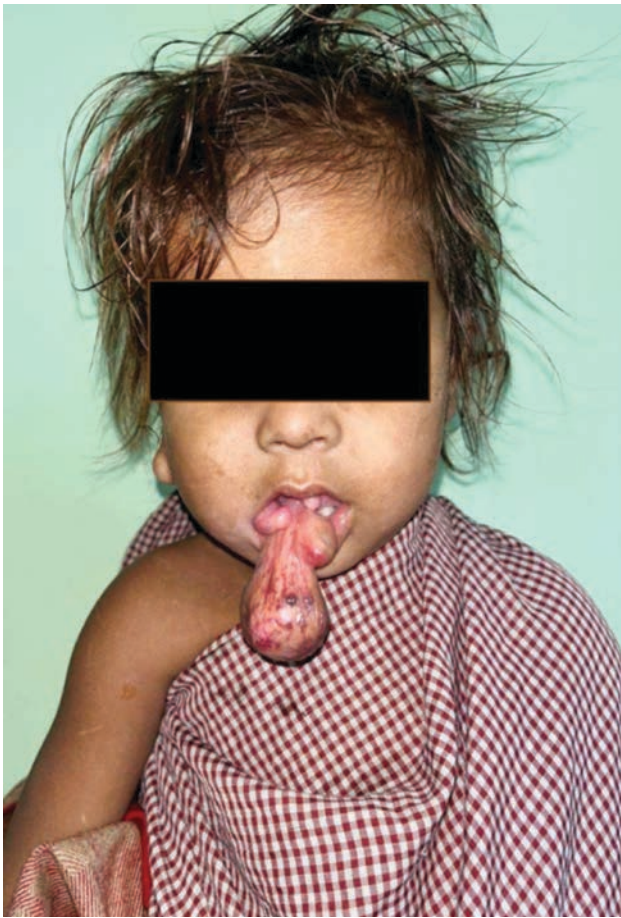The physical examination of the 2-year-old child unveiled a clinical tableau marked by distinctive features, providing valuable insights into the multifaceted nature of the congenital orofacial mass. A prominent and large lobulated, polypoidal mass, measuring 8x4 cm, was identified on the dorsum of the tongue. Its sheer size was striking, with the mass protruding beyond the oral cavity, emphasizing the pronounced impact on oral function and aesthetics. Further examination revealed additional noteworthy findings, amplifying the complexity of the case. A nodular mass, measuring 1x1 cm, was observed at the tip of the tongue, contributing to the overall clinical presentation. Another lobulated mass, measuring 3x4 cm, emerged from the right buccal mucosa, further adding to the intricate nature of the orofacial anomalies. Beyond the oral cavity, the examination unveiled a cleft palate, microphthalmus of the right eye, and an accessory pinna on the right cheek. These associated features, while not directly related to the oral hamartomas, underscored the systemic implications of the condition. The absence of other abnormalities upon systemic examination accentuated the localized nature of the oral pathology, contributing to the delineation of the case's clinical boundaries. The comprehensive examination, combining both localized and systemic assessments, facilitated a holistic understanding of the patient's condition. The detailed observations not only highlighted the immediate challenges posed by the orofacial mass, such as feeding, breathing, and speech difficulties but also hinted at potential underlying syndromic associations or broader developmental anomalies. This intricate clinical snapshot served as the foundation for subsequent investigations and informed the decision-making process regarding the optimal management strategy. The amalgamation of physical findings painted a vivid picture of the complexities involved, guiding the healthcare team in providing tailored and patient-centered care for this rare and challenging case.

## MANAGEMENT

The management of this complex case unfolded with a meticulous and multidisciplinary approach aimed at addressing the challenges posed by the large and symptomatic oral hamartomas in the 2-year-old child.

### Surgical intervention

Given the substantial size and symptomatic nature of the orofacial masses, surgical removal emerged as the primary course of action. The surgical procedure, conducted under general anesthesia with nasal intubation, involved a thorough and com-



FIGURES 1-2. Patients' pictures with lateral view

plete dissection, followed by the excision of the masses from both the tongue and buccal mucosa. The decision to opt for surgical intervention was guided by the necessity to alleviate feeding, breathing, and speech difficulties, which were directly attributed to the size and location of the hamartomas.

**Wound closure**

Post-mass excision, the surgical site underwent meticulous closure in layers using 4-0 vicryl. This careful approach aimed not only to ensure an aesthetically pleasing result but also to promote optimal healing and minimize the risk of postoperative com-

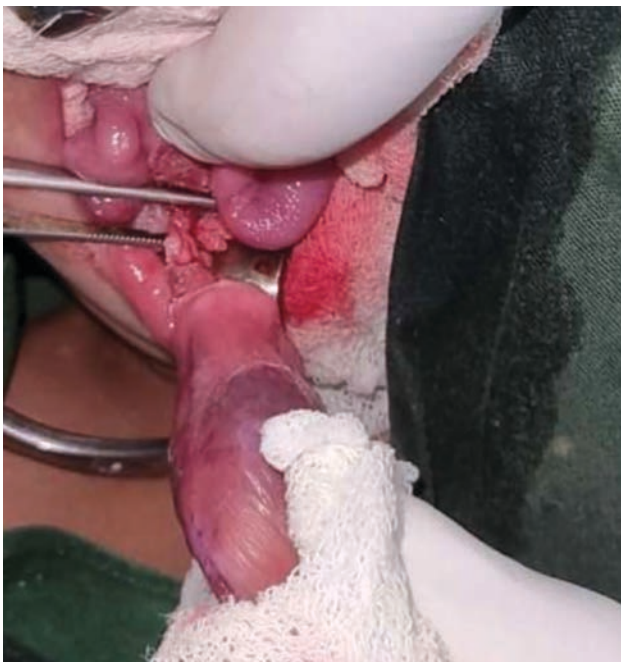

FIGURE 3. Surgical procedure

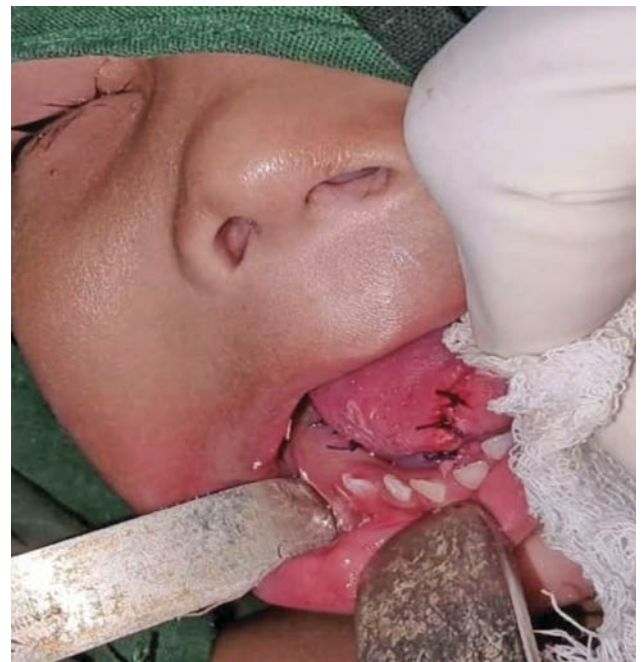

FIGURE 4. Wound closure

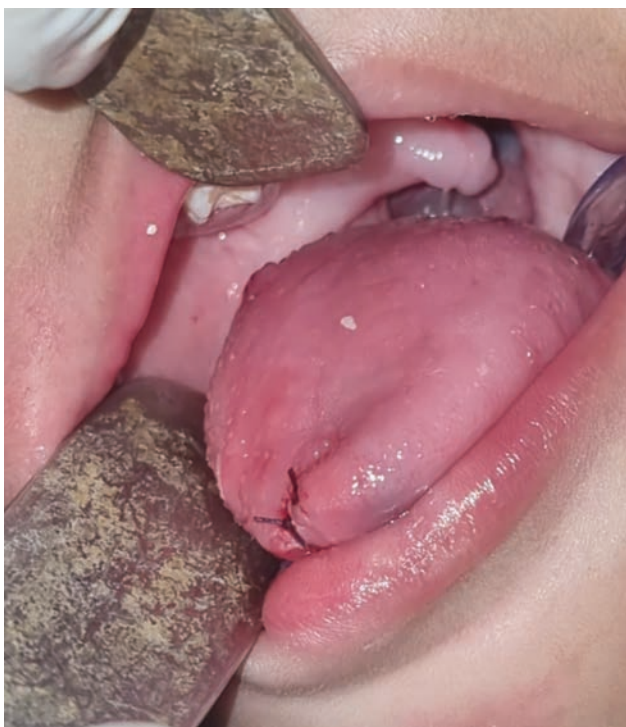plications. The layered closure technique reflected the intricacy of the surgical procedure and underscored the importance of a systematic and comprehensive approach to achieve the best possible outcomes.

### Postoperative course

Following surgery, the child's postoperative course was closely monitored. Remarkably, the child resumed oral feeds on the third postoperative day, signaling a successful and uneventful recovery period. The swift return to oral intake indicated the effectiveness of the surgical intervention in addressing the functional challenges posed by the oral hamartomas.

This management strategy, marked by surgical precision and postoperative care, aimed not only to alleviate immediate symptoms but also to provide a foundation for the child's long-term oral health and overall well-being. The successful navigation of the surgical intervention and the subsequent recovery period underscored the importance of a tailored and patient-centric approach in managing rare and complex pediatric cases with oral hamartomas.

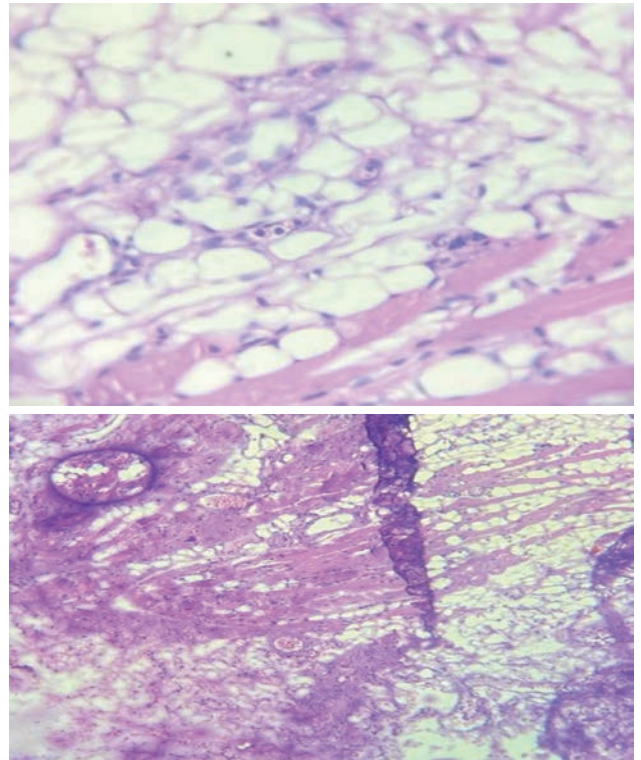
The postoperative phase marked a critical juncture in the management journey, emphasizing the need for ongoing monitoring and follow-up to ensure sustained improvements and to address any potential complications that may arise. The integration of surgical expertise, careful wound management, and vigilant postoperative care collectively contributed to the favorable outcome observed in the child's recovery from this challenging oral condition.



**FIGURE 5.** Post-operative examination

### Histopathological examination

The histopathological examination played a pivotal role in unraveling the intricate nature of the oral hamartomas, providing valuable insights into the composition and characteristics of the excised tissue.



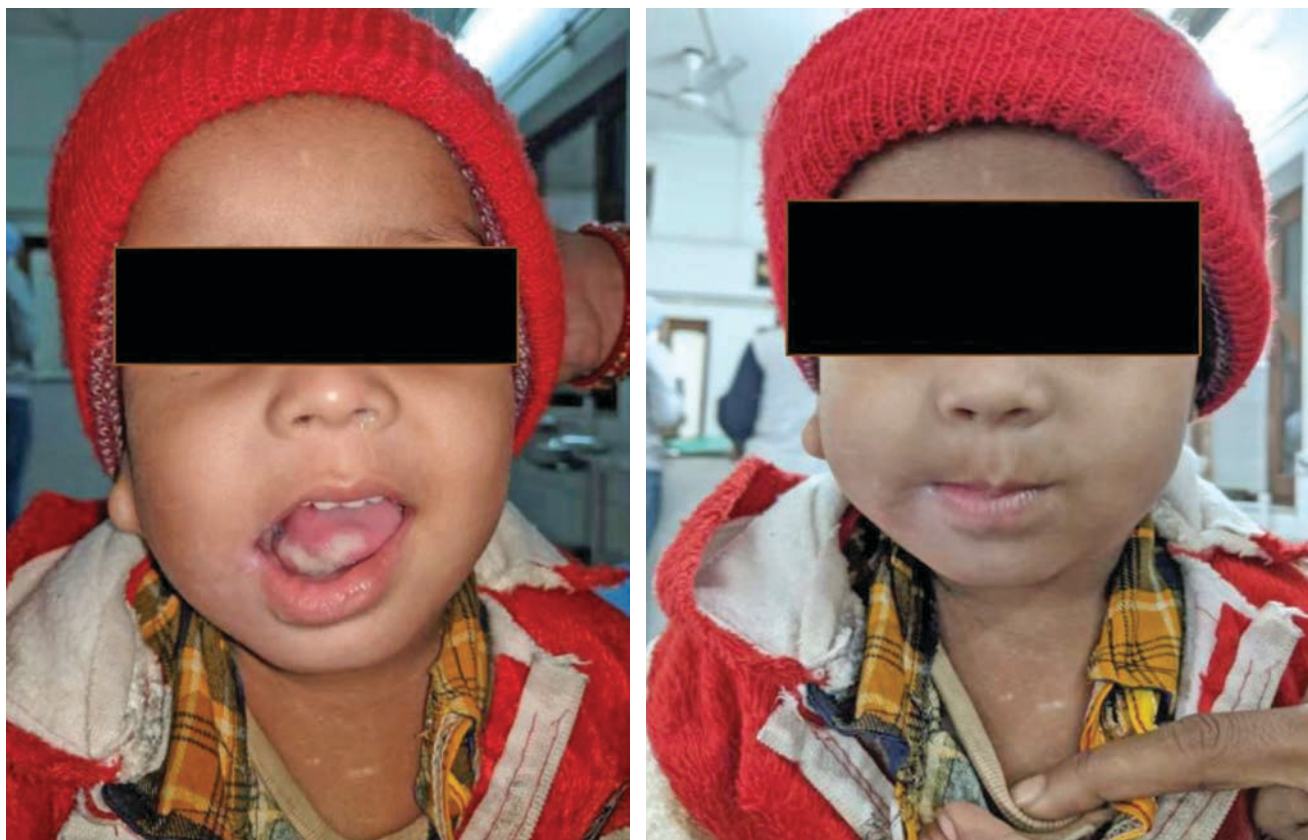**FIGURES 6-7.** Histopathological examination (biopsy)

### Microscopic analysis

The examination revealed tissue fragments exhibiting a complex composition. These fragments were lined by stratified squamous epithelium, indicating the presence of mature epithelial tissue. However, the underlying areas displayed a remarkable admixture of various components. Among these were numerous blood vessels, adipose tissue, fibrocollagenous tissue, cartilaginous tissue, nerve bundles, adnexal structures, and minor salivary glands. This diverse histological profile was consistent with a hamartomatous lesion of the tongue, emphasizing the aberrant proliferation and organization of various tissue types.

### Diagnostic consistency

The findings aligning with hamartomatous lesions of the tongue validated the clinical suspicion and confirmed the definitive nature of the diagnosis. The presence of stratified squamous epithelium, alongside the diverse array of mesenchymal elements, showcased the hamartomatous nature of the oral masses. This histopathological consistency provided a concrete foundation for understanding the underlying pathology and guiding subsequent management decisions.



FIGURES 8-9. Patient recovering

### Implications for understanding

The histopathological examination not only served the purpose of confirming the diagnosis but also offered a deeper understanding of the unique composition of the oral hamartomas. The coexistence of different tissue types within the lesion highlighted the complexity of these benign proliferations, shedding light on the embryological or developmental aberrations that might contribute to their formation.

### Clinical correlation

The correlation between the histopathological findings and the clinical presentation, including the size and vascularity of the oral hamartomas, emphasized the relevance of such microscopic analyses in tailoring patient-specific management strategies. The detailed examination of tissue components provided crucial information that could guide future research endeavors and contribute to the broader understanding of hamartomatous lesions in the oral cavity.

In summary, the histopathological examination served as the definitive step in confirming the diagnosis of hamartomas. Its detailed insights into the tissue composition not only validated the clinical assessment but also enriched the understanding of the underlying pathology, paving the way for informed decision-making in the management of this rare and complex pediatric case.

### CONCLUSION

In conclusion, the presented case of large and multiple oral hamartomas in a non-syndromic 2-year-old child adds a distinctive dimension to the realm of oral pathology. Lingual hamartomas, though relatively rare, emerged as the central focus of this clinical narrative, highlighting their significant impact on critical functions such as feeding, breathing, and speech. The exceptional size and vascularity of the hamartomas showcased the atypical nature of this presentation, contributing valuable insights to the evolving understanding of oral hamartomas. The comprehensive examination, surgical intervention, and histopathological examination collectively provided a nuanced exploration of this unique case, underscoring the necessity for a multidisciplinary and tailored approach in managing such complex pediatric conditions. This case serves as a reminder of the importance of considering hamartomas in the differential diagnosis of tongue lesions in pediatric patients. The rarity of non-syndromic occurrences, as evidenced by a limited number of cases reported in the literature, accentuates the uniqueness of this presentation.

Definitive management, as demonstrated in this case, involved meticulous surgical excision, facilitated by a detailed understanding of the clinical, radiological, and histopathological aspects. The successful postoperative course, marked by the swift resump-

tion of oral feeds, attests to the efficacy of the chosen management strategy and underscores the potential for positive outcomes in challenging cases.

The histopathological examination not only confirmed the diagnosis but also provided a deeper understanding of the diverse tissue components within the hamartomas. This knowledge contributes to the broader comprehension of the embryological or developmental factors at play in the formation of these benign proliferations. As we reflect on this case, it emphasizes the need for ongoing research, collabora-

tion, and documentation to expand the collective knowledge surrounding oral hamartomas. Each unique case adds a layer of complexity to the existing body of literature, enriching our understanding of these rare entities.

In conclusion, the successful management of this non-syndromic case exemplifies the importance of a comprehensive and patient-centered approach, leveraging clinical expertise, surgical precision, and histopathological insights to navigate the intricacies of oral hamartomas in the pediatric population.

*Conflict of interest:* none declared

*Financial support:* none declared

## REFERENCES

1. Liu Y-C C, Shih M, Hicks MJ, Sitton MS. Lingual Hamartomas. *Laryngoscope*. 2021;131:E2080–E2088. doi: 10.1002/lary.29284.
2. Vashishth A, Mathur NN, Choudhary SR, Khanna G. Giant vascular hamartoma of the tongue. *Malays J Med Sci*. 2014 Mar;21(2):74-7. PMID: 24876812; PMCID: PMC4028576.
3. Kreiger PA, Ernst LM, Elden LM, Kazahaya K, Alawi F, Russo PA. Hamartomatous tongue lesions in children. *Am J Surg Pathol*. 2007 Aug;31(8):1186-90. doi: 10.1097/PAS.0b013e3180674dd7. PMID: 17667541.
4. de Faria PR, Batista JD, Duriguetto AF Jr, Souza KC, Candelori I, Cardoso SV, Loyola AM. Giant leiomyomatous hamartoma of the tongue. *J Oral Maxillofac Surg*. 2008 Jul;66(7):1476-80. doi: 10.1016/j.joms.2007.06.679. PMID: 18571033.
5. Stamm C, Tauber R. Hamartoma of tongue. *Laryngoscope*. 1945;55(3): 140-146. doi: 10.1288/00005537-194503000-00005.